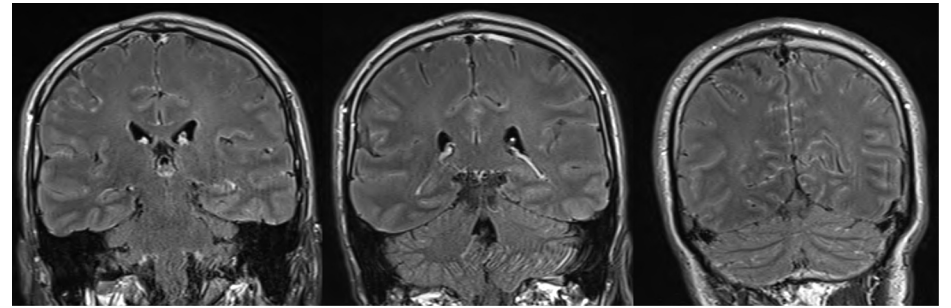


• 2 Viral meningitis in an adult

Contrast-enhanced FLAIR images showing diffuse leptomenigeal enhancement.



Context

46-year-old man with headache, fever and neck stiffness. CSF lymphocytic pleocytosis. No bacterial agent. Leptomeningitis on brain MRI.

What to note

Bilateral frontal intermittent rhythmic delta activity (FIRDA) activity at 2 Hz. FIRDA increases during and after hyperventilation.

Comment

The pattern of intracranial hypertension was not recognized by the EEG-technician. Hyperventilation should be avoided in this situation.

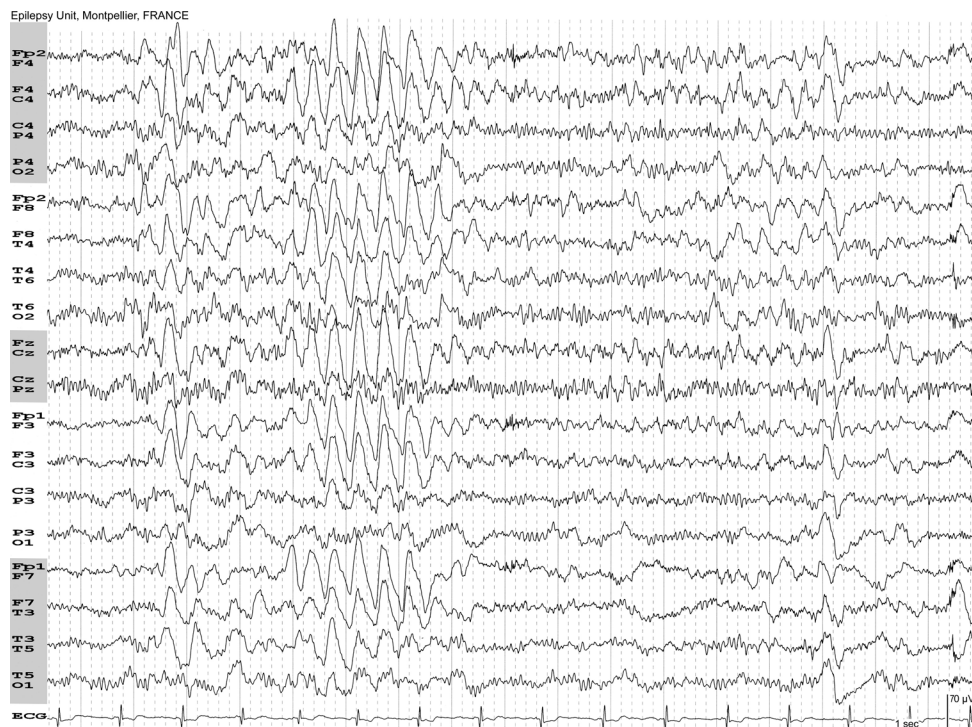


Figure a / Recording at 15 mm/s.

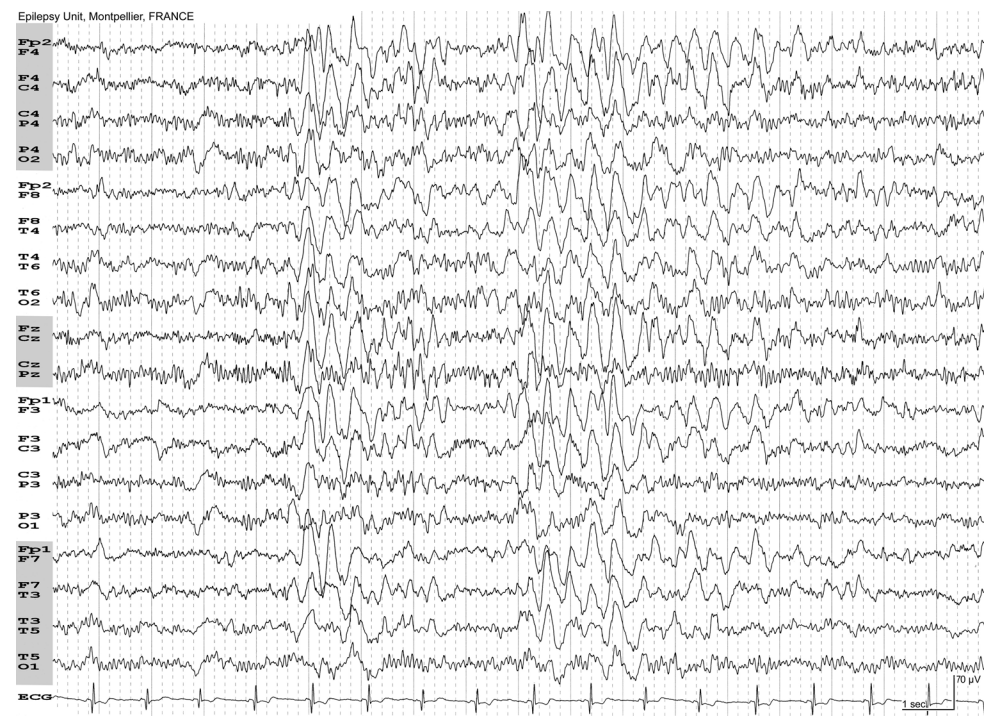


Figure b / Recording at 15 mm/s. Increased FIRDA after hyperventilation.

Epilepsy Unit, Montpellier, FRANCE

